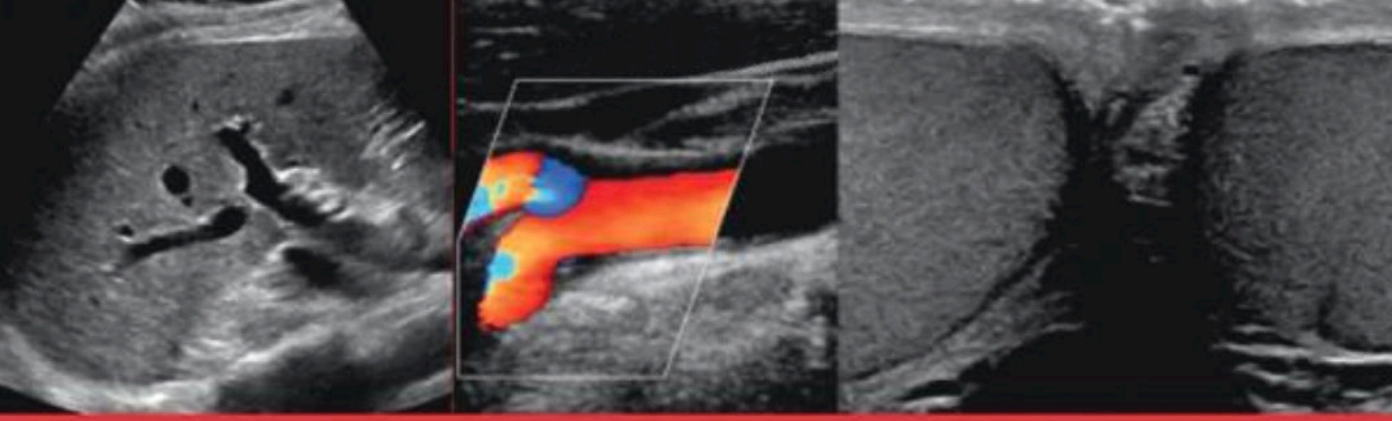

Sonography Scanning

PRINCIPLES AND PROTOCOLS

FIFTH EDITION

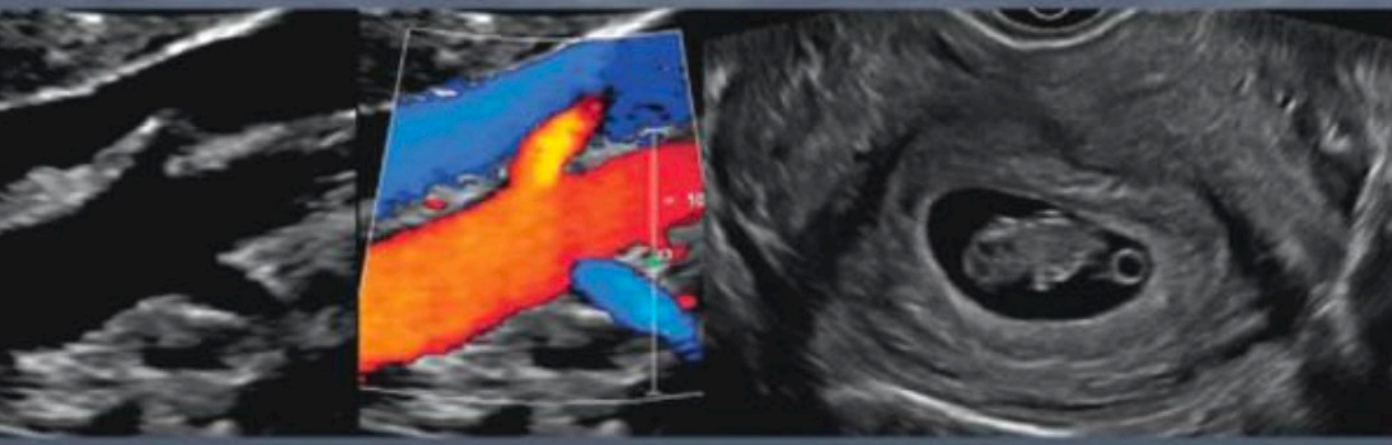

M. Robert De Jong

ELSEVIER

Evolve®

Student Resources on Evolve
Access Code Inside

Sonography Scanning

PRINCIPLES AND PROTOCOLS

Preface

It is an honor that I was once again asked to revise a textbook loved and used by many students, teachers, and sonographers. I have been a sonographer since 1976, and it is my hope that some of the tips and tricks I have learned over the years will help students and anyone reading this book be better sonographers. I wanted to add some new sections, including liver elastography, neonatal hips and spine, and neck mapping. Unfortunately, that meant some material had to be cut to make room for the new material. It was not an easy decision, but I decided to eliminate the echocardiography section. The main reason I decided to not include these chapters is that the field of echocardiography has exploded with new technologies, and I felt it would not be fair to the reader to have a basic chapter, nor would it give the echocardiography profession the justice it deserves. I also agreed with Shannon to combine the obstetrics chapter with the obstetric transvaginal scanning chapter, because very rarely would just a transvaginal examination be ordered for a pregnancy, but it would be performed at the time of the transabdominal study to clarify findings.

One of the most frustrating things for a student is understanding why it appears that every sonographer scans a patient differently, giving the impression that they are following different protocols. In addition, there is the conflict between the protocol they learn in school and the one the sonographer follows in the clinical rotations. It is my hope that by reading this book the student understands that all studies have a basic protocol as defined by the ultrasound societies and accrediting organizations, which allows the department to add additional images that it may require for the practice. Some sonographers may prefer to start with transverse images, whereas others prefer to begin with longitudinal images, which can add to the confusion. The bottom line is that sonographers document the required images by the end of the study. Sonography is unique in that it allows some freedom in image order and expansion of the protocol as needed when pathologic findings are present. As sonographers, we develop our own style of scanning over the years.

Sonography is the most operator-dependent modality, and the skills and knowledge of the sonographer will determine the quality and findings of the sonographic images. As sonographers, we constantly use our critical thinking skills to optimize images and determine which images to document to provide a complete study to radiologists or sonologists, so they can determine if the study is normal or if a pathologic condition is present. Sonographers must know what a normal organ or Doppler signal looks like so they can determine if what they are seeing is abnormal. A sonographer needs

a good understanding of sonographic principles and instrumentation to obtain high-quality images. The ultrasound unit can only do so much for the image, and the sonographer must take the image to the next level by adjusting the proper controls and choosing the correct transducer type and frequency.

All of the chapters follow a similar structure and are divided into three sections. The chapter begins by starting with a review of anatomy and physiology, followed by the sonographic appearance of the organ and any normal variants. The next section deals with scanning the organ: discussing patient prep, appropriate transducers, and the right patient position or positions to use while scanning. Rounding out this section are discussion of breathing techniques needed and technical tips for a successful study. The final section is the protocol for the study. All protocols were current at the time of writing the book and are based on the American Institute of Ultrasound in Medicine (AIUM) practice parameters and the Intersocietal Accreditation Commission Vascular Testing (IAC-VT) standards. The AIUM protocols were not created solely by the AIUM but have been created and approved jointly by the major ultrasound, radiology and other medical organizations that use ultrasound in their daily practice. This makes following a protocol much easier than deciding whether to follow the AIUM or ACR protocol, for example. The IAC-VT standards are only for vascular examinations and are very similar if not identical to the AIUM guidelines.

What's New

This edition has been updated to reflect current required minimum images for sonographic examinations based on the AIUM guidelines and IAC-VT standards at the time of publication. There are all new images to illustrate the images required for protocols and some examples of common pathologic conditions that might be found incidentally. With the increase of information and images, the review questions have been moved online. In addition, you will notice that the survey information has been removed. With current constraints on the amount of time to complete a sonogram, sonographers do not have the time to perform a whole protocol before they start documenting images. Many sonographers start the examination and see what unfolds as they are scanning. Some sonographers may do a quick survey before starting the documentation process by maybe scanning the organ in one plane, usually transverse. It does not make you a poorer sonographer if you do not do a survey scan before you start the examination. To be honest, I never did a pre-scan survey. If the purpose of the sonogram is to verify or clarify findings from another imaging study, I would pay special attention to the area in

question when I examined that area. Usually at the end of the study I would document a few images using a split screen technique and obtain longitudinal and transverse images of any mass or pathologic finding with measurements. I would also add any images at the end as needed to document areas of pain or concern, again in longitudinal and transverse planes, that were not evaluated with the normal protocol images.

It is my hope as you journey along your road to becoming a great sonographer that this book will help you in your travels.

M. Robert De Jong, RDMS, RDCS, RVT, FAIUM, FSDMS

Contents

APPENDIXES

CHAPTER 1

Understanding Protocols and How They Are Determined

M. Robert DeJong

Key Words

Accreditation
As Low As Reasonably Achievable (ALARA)
Case presentation
Congenital anomaly
Current Procedural Terminology (CPT) code
Decubitus
Electronic Medical Record (EMR)
Ergonomics
Health Insurance Portability And Accountability Act (HIPAA)
Identification (ID) bracelet
Pathologic condition
Personal Protection Equipment (PPE)
Protocol
Scope of practice
Sonographer
Sonologist

Objectives

At the end of this chapter, the reader will be able to:

- List the organizations that determine which images are needed for a protocol
- Discuss the difference between a complete and limited Current Procedural Terminology (CPT) code
- Discuss how congenital anomalies and pathologic conditions can influence the final protocol
- Define ultrasound terms used to describe the ultrasound appearance of structures

Who and What Determines a Protocol

Protocols can be very frustrating to a student or a new employee. What exactly is a protocol? In ultrasound a **protocol** determines the images needed to ensure that a diagnosis can be made or verify that an organ is normal. The **sonographer**, using sound waves to create images of the body, is responsible for obtaining the images of a protocol. Although protocols may differ among laboratories, all have a core of similarity. For example, hospital A may require the right kidney to be fully imaged in a right upper quadrant (RUQ) examination, whereas hospital B may require only a long-axis image of the right kidney with a measurement. What is the reason for these differences? Shouldn't protocols be uniform across the country?

Ultrasound Organizations

The good news is that our national ultrasound organizations and those medical organizations that use ultrasound, such as The American College of Obstetricians and Gynecologists (ACOG), are working with the ultrasound **accreditation** organizations that evaluate the ultrasound practice for the quality of their studies, reports, and policies to help standardize ultrasound protocols. These organizations include the American Institute of Ultrasound in Medicine (AIUM), Society of Radiologists in Ultrasound (SRU), American College of Radiology (ACR), Society of Pediatric Radiologists (SPR), the Society for Maternal-Fetal Medicine (SMFM), Society of Interventional Radiology (SIR), and ACOG. For protocols in which the sonographic examination may be performed by different specialties, the organization associated with that protocol was invited for collaboration. For example, for any urology-related protocols, the American Urologic Association (AUA) had input because some urologists perform ultrasound examinations in their office.

Accrediting Organizations

The common denominator of protocols is the requirements of the accreditation organizations, because their standards will require a minimum set of images to be accredited by that organization. Accreditation is required for reimbursement by some insurance companies. A department may add additional images or views to the protocol, but they may not delete required images. Accrediting organizations include the AIUM, ACR, and Intersocietal Accreditation Commission–Vascular Testing (IAC-VT). The ACR and IAC-VT provide accreditation for laboratories or departments that perform vascular examinations, and the AIUM for departments that perform ultrasound examinations that are not vascular. The AIUM has vascular protocols on their web site but they do not offer vascular accreditation through AIUM accreditaion. Working with IAC, they provide accreditation for all aspects of ultrasound accreditation. The ACR accredits both vascular and nonvascular examinations, and most radiology ultrasound departments prefer ACR accreditation, as they offer accreditation for all the imaging modalities in a radiology department. Most vascular laboratories receive their accreditation through IAC-VT, and nonimaging departments that perform their own ultrasound examinations, such as urology and endocrine departments, achieve accreditation through the AIUM. Protocols and accreditaion standards should be checked annually and can be found on each of the organization's web site.

Coding

Another aspect that influences protocols is the billing codes that are sent to the insurance companies, called the Current Procedural Terminology codes, or, more commonly, **CPT codes.** The main purpose of the CPT code is to define what constitutes a complete versus a limited ultrasound examination. The internal code used by the ultrasound department, such as US123, which is used to order a renal ultrasound, is mapped to CPT code 76775. The 76775 code, not the US123 code, is sent to the insurance company for billing. The CPT code 76775 is used to bill an "ultrasound, retroperitoneal (e.g., renal, aorta, nodes), real time, with image documentation, limited." The CPT book defines which images are needed to legally bill for a complete study. A complete retroperitoneal study, 76770, is defined as follows: a complete ultrasound examination of the retroperitoneum consists of real-time scans of the kidneys, abdominal aorta, common iliac artery origins, and inferior vena cava, including any demonstrated retroperitoneal abnormality. Alternatively, if clinical history suggests a urinary tract pathologic condition, complete evaluation of the kidneys and urinary bladder also comprises a complete retroperitoneal ultrasound. This means that if your department bills 76770 for a renal ultrasound and the bladder is not imaged or mentioned in the final report, the insurance company will reject the bill, since the CPT code submitted was by definition a complete study and a limited study was performed. Once rejected, the department may not be able to bill again for the study. If a practice is caught billing for complete studies when only performing limited studies, they are heavily fined. The structures that need to be imaged to constitute a complete study are found in the CPT book and should be checked with each new edition to update protocols as needed.

FUTURE OF IMAGE STORAGE: As technology evolves, our protocols evolve also. Some laboratories now include video clips of the anatomy along with still images, whereas other laboratories take only video clips. With volume imaging, some laboratories acquire volumes of data and "slice and dice" the data like computed tomography (CT) and magnetic resonance imaging (MRI). There will be new ways to document and store the images as the industry evolves.

How Congenital Anomalies and Pathology Influence the Protocol

The sonographer must be knowledgeable and aware of congenital anomalies, because these will require adjusting the protocol. A

congenital anomaly is defined as something that is unusual or different at birth, such as a choledochal cyst or ectopic kidney. If a sonographer discovers a kidney is not in its correct location, this cannot be ignored, but rather the protocol should be expanded into the pelvic region to locate the missing kidney. If the kidney in the normal position is normal in size, there is a second kidney somewhere in the body, as a solitary kidney would be increased in size.

The protocol will be expanded when a **pathologic condition** is found. An example would be in the finding of unsuspected liver metastases; in this case the protocol should be expanded to try to determine the primary tumor and look for abdominal lymph nodes. Another example is when ascites is discovered on a RUQ ultrasound examination. Once ascites is discovered, the full extent of the fluid should be documented, which will entail scanning the flanks, the pelvic area, and the left upper quadrant (LUQ). Sometimes an obvious cause for the patient's symptoms is not diagnosed, and the sonographer needs to keep looking. For example, if a patient presents with bilateral leg swelling, yet no deep vein thrombosis (DVT) is found in the leg veins, the sonographer should expand the protocol to image the inferior vena cava to look for a central clot.

Nonimage Aspects of Protocols

Protocols do not just tell the sonographer what images are needed but also inform the sonographer about patient positions, transducer types and frequencies, required patient preps, and other information. In addition, protocols may tell the sonographer how to alter the protocol when congenital anomalies or pathologic conditions are present and what images are needed for short-term follow-up examinations.

Protocol: Patient Positions and Scanning Planes

Protocols will describe the best patient position to obtain the needed images and any specific patient positions required. For example, a protocol for the gallbladder will have the patient start in a supine position and require, depending on the patient's condition, turning the patient into a left lateral **decubitus** position, also called a right side up (RSU) position. A decubitus position is when the patient lies on their side, with the side that is on the table, or down, stated before the word "decubitus." Other patient positions include prone, oblique, and erect views. Various patient positions are illustrated in Fig. 1.1.

All protocols will require images obtained in at least two planes, usually the longitudinal and transverse planes. Other imaging planes may include oblique, coronal, sagittal, and the long axis of the organ.

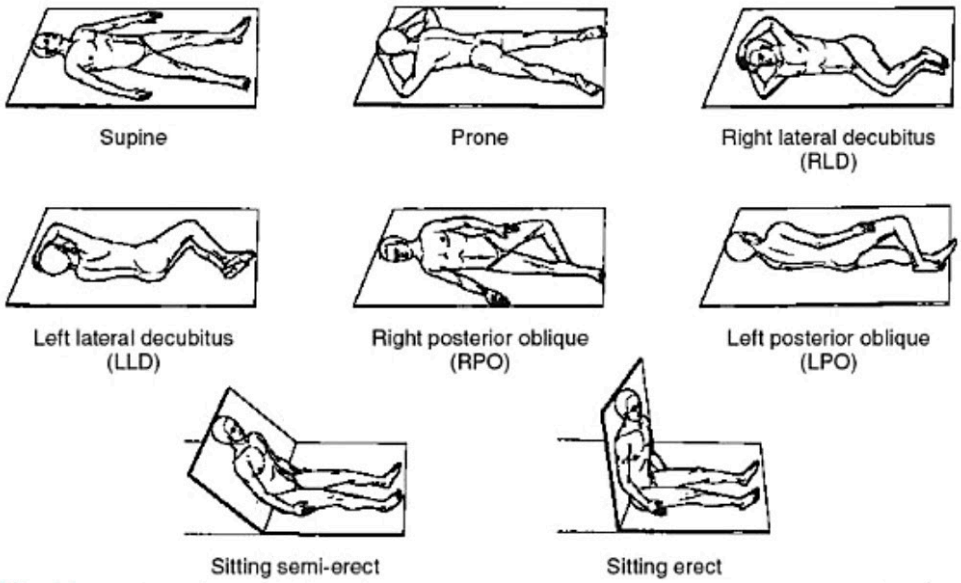

Fig. 1.1 Standard Patient Positions. Different patient positions are used during an ultrasound examination depending on the area of interest being evaluated. The best patient position is determined by what will produce the optimal view. It is standard practice to use different patient positions during a study to evaluate various structures. Note that any change in patient position must be noted on the images as part of standard labeling.

Protocols: Documentation

As technology grows and the cost of storing images on a server is decreasing, documentation of ultrasound studies is changing. One limiting factor is the size of video clips that the picture archiving and communication system (PACS) can play, although this is no longer an issue with modern PACS. The number of images required for documentation may change between ultrasound departments. This is especially true with the increasing number of departments integrating video clips into their protocols. The sonographer may obtain these video clips while assessing the anatomy to determine whether the organs seen are normal or affected by a pathologic condition. Using a scanning protocol is essential for methodical and organized documentation and for future comparable studies. Follow a scanning protocol as you would follow steps in a recipe.

The Sonographer and the Patient

- Dress according to the department's guidelines. Many institutions are adopting department color-coded uniforms or scrubs so the area the employee works in can be easily identified. For example, diagnostic imaging personnel, no matter what department they work for, may wear blue uniforms, and nurses may wear green uniforms. Make sure you know the guidelines for, wearing jewelry, visible body piercings, and tattoos. If you are allowed to wear street clothes, make sure you know what is acceptable and what is not

acceptable to wear. Gel and body fluids can stain your clothes (I cannot begin to count my gel-stained ties), so make sure these are clothes that can be washed; stain-removal laundry products can help with gel stains. Consider investing in a few laboratory coats if you are allowed to wear them. Remember that your identification badge is part of your uniform and should be worn at all times while on the job and displayed so your name can be easily seen. You are a representative of the place where you work, so dress accordingly.

- Introduce yourself to your patient as soon as possible, which may be when you go to the waiting area to escort them back to the scanning room.
- Make sure you have the correct patient by checking the inpatient **identification (ID) bracelet**; some hospitals and outpatient centers are also placing them on outpatients. The typical ID bracelet displays the patient's full name, date of birth, and hospital identification or medical record number. If the patient does not have an ID bracelet, identify the patient as required by your place of employment. Some departments will not let you scan an inpatient who is missing their ID bracelet until one is placed on the patient. Although usually on the patient's wrist, they may be found in other places on the patient's body, such as their ankle.
- Briefly explain the examination to the patient in layman's terms. For example, tell the patient that he or she will need to roll on the left side when instructed, as opposed to needing to roll into a decubitus position. Be sure to ask if the patient has any questions or concerns before beginning the examination. Make sure that you speak clearly and at a slow pace.
- When indicated, obtain a brief medical history from either the patient or the patient's **EMR** and obtain any needed lab values and operative or other imaging reports. The EMR replaces the patient's physical chart and contains information on the patient such as physical findings, vital signs, operative notes, laboratory values, imaging reports, and physician notes, among other information. Avoid using medical terms a patient may not understand when asking questions about history pertinent to the examination.
- Always be professional, courteous, and respectful to your patients, co-workers, and other staff.
- When in public areas, do not discuss patient information or tell patient stories. Be careful with what you put on social media about work and using social media as a place to complain, especially about a patient that you scanned. People have lost their jobs over improper social media content. As remote as it seems, your comments can be seen as a HIPAA violation. **HIPAA** is a U.S. law designed to provide privacy standards to protect patient medical records and other health-related and personal information that the patient or guardian provided to health plans, doctors, hospitals, and other health